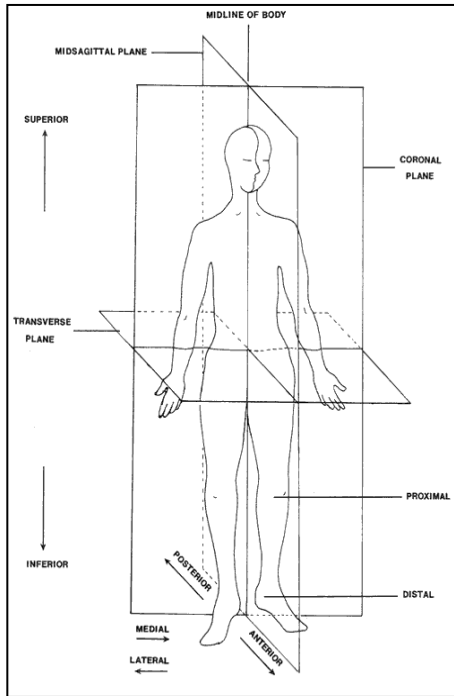


Frames of Reference

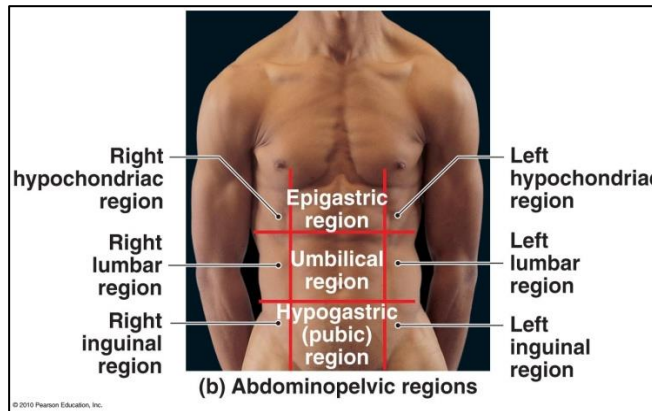


Directional Terms in Human Anatomy:

Anterior	Towards the front
Ventral	Towards the front
Posterior	Towards the back
Dorsal	Towards the back
Deep	Away from the surface
Superficial	On the surface
Proximal	Near the point of attachment or origin
Distal	Far from the point of attachment or origin
Inferior	Below another structure
Superior	Above another structure
Medial	Towards the midline
Lateral	Away from the midline
Supine	Lying on back
Prone	Lying on belly
Contralateral	On the opposite side of the body
Ipsilateral	On the same side of the body
Rostral	Towards the forehead or nose
Caudal	Towards the tail or inferior end
Cephalic	Towards the head or superior end

Abdomen Quadrants:

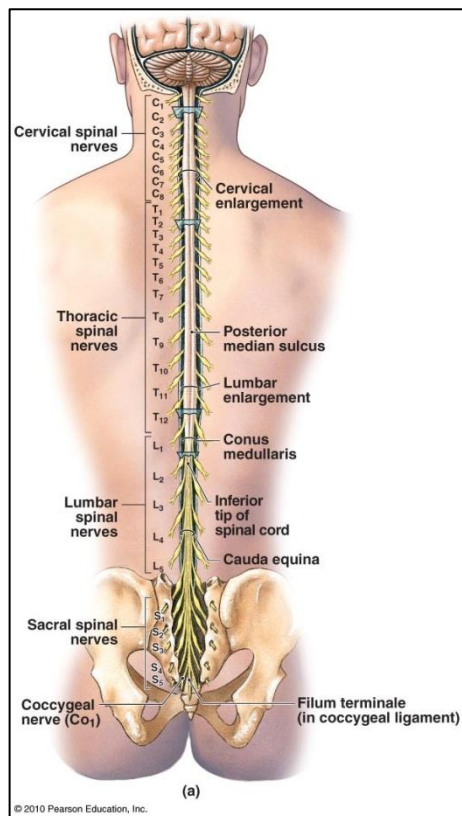
Right Upper	Left Upper
Right Lower	Left Lower



Regional Terms:

cephalic = head
mammary = breast
nasal = nose
orbital = eye
oral = mouth
cervical = neck
acromial = shoulder
sterna = breast bone
axillary = armpit
vertebral = spinal
occipital = base of skull
perineal = between anus & genitalia
femoral = thigh
thoracic = chest
costal = rib
brachial = arm

carpal = wrist
digital = fingers/toes
pubic = genital
antebrachial = forearm
manus = hand
abdomen = abdominal region
lumbus = lumbar (loin) region
gluteus = buttocks
pelvis = pelvic region
inguen = groin
crus = anterior leg
sura = calf
tarsus = ankle
pes = pedal (foot) region
planta = sole of foot



Divisions of Spinal Column:

Cervical	Neck region C1-C8
Thoracic	Chest region T1-T12
Lumbar	Between ribs & hipbone L1-L5
Sacral	S1-S5 fused to form sacrum
Coccygeal	Coccyx (tailbone)

